

CASE REPORT

DOI: 10.15517/IJDS.2022.51475

Received:
10-IV-2022

Congenital Granular Cell Tumor of the Newborn. A Case Report and Literature Review

Accepted:
14-VI-2022

Published Online:
20-VI-2022

Tumor congénito de células granulares del recién nacido.
Reporte de caso y revisión de la literatura

María del Carmen Navas-Aparicio DMD, MSC¹; Alejandro Acuña-Navas MD²;
Diego Guillén Colombari MD³

1. Universidad de Costa Rica. Cleft Lip and Palate-Craniofacial Unit. Hospital Nacional de Niños Dr. Carlos Sáenz Herrera, Caja Costarricense de Seguro Social. Costa Rica. San José, Costa Rica. <https://orcid.org/0000-0001-7273-8432>

2. Independent Researcher. San José, Costa Rica. <https://orcid.org/0000-0003-4181-6682>

3. Universidad de Costa Rica. Caja Costarricense de Seguro Social. Costa Rica. San José, Costa Rica. <https://orcid.org/0000-0002-5032-093X>

Correspondence to: Dr. María del Carmen Navas-Aparicio - MA.NAVAS@ucr.ac.cr

ABSTRACT: A congenital granular cell tumor is a benign and rare tumor of the oral cavity, which occurs exclusively in newborns and can cause, due to its size, a mechanical obstruction of the airway, and consequently, respiratory problems and feeding problems. Therefore, early diagnosis and treatment is important to promote the quality of life of both the patient and the parents. The purpose of this report is to (i) present the case of a patient diagnosed with congenital granular cell tumor (congenital epulis), its treatment and evolution and (ii) a review of the related literature because although its incidence is low, it is estimated that in 0.0006% of the cases the consequences are of important consideration if adequate management is not given.

KEY WORDS: Congenital epulis; Congenital epulides; Congenital granular cell tumor; Gingival neoplasm; Newborn; Infant; Alveolar process.

RESUMEN: El tumor de células granulares congénito es un tumor benigno y raro de la cavidad oral, que se presenta exclusivamente en recién nacidos, el cual puede ocasionar, debido a su tamaño, obstrucción mecánica de la vía aérea y por tanto problemas respiratorios, así como problemas de alimentación, por lo que el diagnóstico y tratamiento temprano es importante para favorecer la calidad de vida del paciente

y de los padres. El propósito de este reporte es (i) presentar el caso de una paciente con el diagnóstico de tumor de células granulares congénito (épulis congénito), su tratamiento y evolución, y (ii) la revisión de su literatura, pues si bien su incidencia, es baja, y se estima en 0.0006%, sus consecuencias son de importante consideración si no se le brinda el manejo adecuado.

PALABRAS CLAVE: Épulis congénito; Epulides congénito; Tumor de células granulares congénito; Neoplasma gingival; Recién nacido; Infante; Proceso alveolar.

INTRODUCTION

A congenital granular cell tumor is a benign and rare tumor located in the oral cavity, which occurs exclusively in newborns (1-15). It was first described in 1871 by Neumann (1,2,4,5,7,8,10-14).

It is also known by other different names, such as congenital epulis (2,5,6,10,13-15), congenital granular epulis (2), epulis of the newborn (6,12,13), congenital granular cell myoblastoma (2,10,12), congenital granular cell fibroblastoma (2,12), gingival granular cell tumor of the newborn (6,7,12), and Neumann's tumor (5,7,10,12,15), among others.

According to Boanquet and Roblin (2009), the incidence of congenital epulis in Wales has been of 0.0006% in a period of 28 years (3), but there are no other specific related studies.

The congenital granular cell tumor or congenital epulis is characterized by being a soft, firm, well-circumscribed, single tumor with a smooth surface (1,2,4-6,9-13). It can be multilobed (1,2,11), sessile or pedunculated, pinkish or reddish in color (1,2,4,5,8-13,15). It is located at the level of the anterior alveolar ridge, mainly in the maxillary region (1,2,4-12,15). Although the diagnosis could be based only on clinical criteria, an histopathological study and histochemical findings are essential to determine the exact diagnosis and the appropriate management of the tumor (1-5,9,12-15). The treatment of choice is surgical excision, which is performed immediately after the diagnosis

(1-5,7-10,12-15) and has an excellent prognosis (4,15).

Below is a case report of a newborn patient with a diagnosis of congenital granular cell tumor in the antero-superior alveolar ridge and a review of the literature on this pathology.

CASE REPORT

A 6 days old female patient was referred to oral and maxillofacial surgery consultation by the pediatrician because she presented, since birth, a tumor in the region of the maxillary anterior alveolar ridge, which caused her difficulty when feeding, but not when breathing since it did not obstruct the oral cavity.

A clinical examination was performed, revealing an oval tumor in the upper anterior rim, temporal upper central and lateral incisor region, pale pink like the surrounding structures, pedunculated, but with a wide base, approximately 15-mm in size, without any symptoms on palpation (Figure 1). Due to the characteristics of the lesion, a congenital granular cell tumor was suspected (i.e., a soft tissue tumor that does not compromise hard tissues such as bone and tooth germs), and therefore there was no need for imaging studies. Although the diagnosis was made based on characteristic clinical findings, a differential diagnosis should be considered with other congenital malformations, and other benign and malignant neoplasms that are described later. No other malformation was observed in the oral cavity.

The patient was classified as Asa I and her blood count was normal.

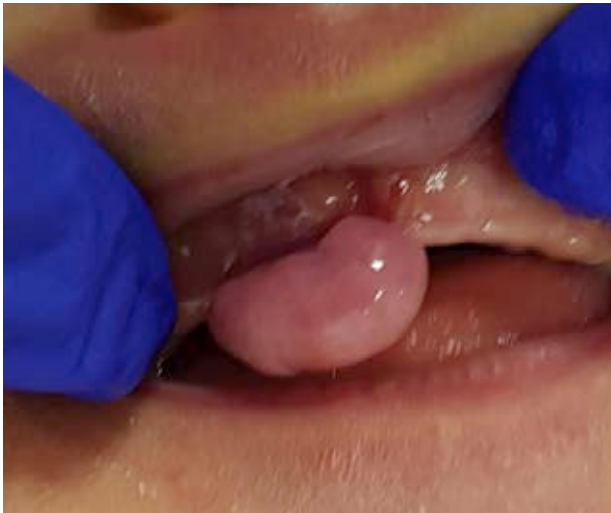

Figure 1. Congenital granular cell tumor in the anterior-superior maxillary alveolar ridge, region of the upper right temporal incisors, with an approximate size of 15-mm in length, in a newborn female patient.

The proposed treatment was outpatient, based on an excisional biopsy of the tumor under local anesthesia (lidocaine with epinefrina), with prior consent of the parents. Excision was performed with a scalpel by cutting the tumor in the mucosa of the basal region in the area of the pedunculated tissue adjacent to the alveolar ridge. Subsequently, absorbable sutures were placed to help partially close the wound. There was a minimal blood loss and there was no need for any additional treatment. The procedure was performed without any complication and Acetaminophen

40mg orally every 6 hours was prescribed as an analgesic. The tissue obtained was sent to Pathology for histopathological study in 10% formalin. Two weeks later, during the postoperative control, good tissue healing was observed.

The histopathological report described a 15-mm round tissue fragment, lined by unaltered squamous epithelium, and beneath it an accumulation of monotonous cells with small nuclei without pleomorphism and abundant hyaline and markedly granular cytoplasm. The cells were arranged in dense sheets with intercalated blood vessels (Figure 2. A-C). No malignancy was observed. It did stand out that tumor cells were located right at the resection margin. An immunohistochemistry study was performed, revealing the following: staining with S100, SOX10 and Pancytokeratin were negative, and Vimentin was positive (Figure 3). The histopathological diagnosis was granular cell tumor of the newborn (epulis of the newborn).

Eleven months later, it was observed that the temporal right upper lateral incisor, the temporal left upper central incisor and temporal lower central incisors teeth were in the process of eruption. The temporal right upper central incisor and temporal left upper lateral incisor teeth were soon to erupt, as the incisal edge of thereof was palpable on the alveolar ridge.

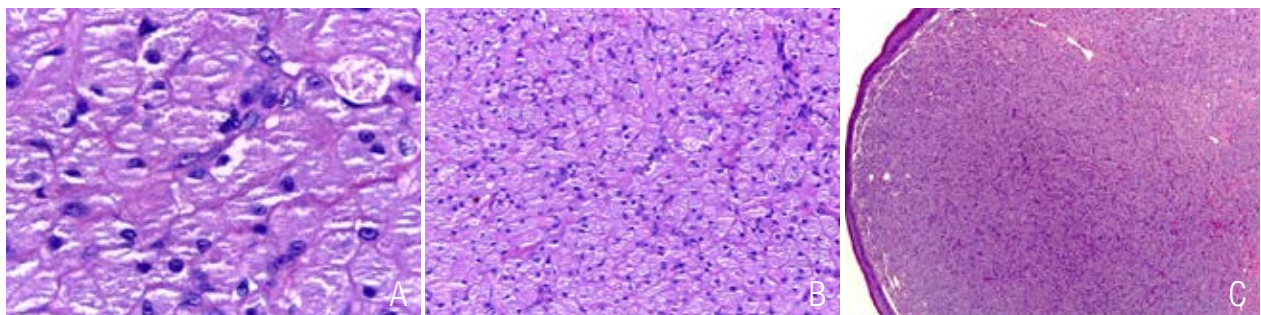


Figure 2. A. Granular cells. Granular cells possess a granular cytoplasm and a centrally located small nucleus. H&E, 63X. B. Granular cells form a solid sheets of tumor cells. H&E, 20X. C. The overlying epithelium is atrophic in contrast with that of the granular cell tumor of the adult, where the epithelium shows pseudoepitheliomatous hyperplasia. H&E, 4X.

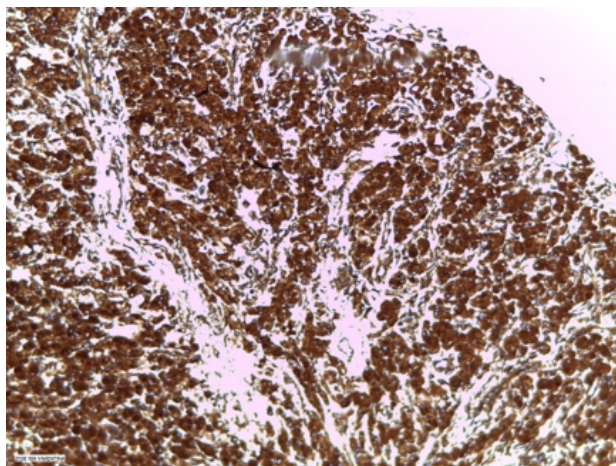


Figure 3. Immunohistochemistry study with Vimentin staining was positive. 10X.

DISCUSSION

Congenital granular cell tumor is a benign and rare tumor of the oral cavity, occurring exclusively in newborns (1-15), with variable size, which can cause respiratory and feeding problems due to obstruction of the airway (1-5,7-15). In the instant case, although the size of the tumor was large (i.e., about 15-mm), it did not obstruct the oral cavity and therefore did not cause respiratory problems, but it did cause feeding problems when the female tried to suck as she exerted pressure against the tumor. Even in the literature, cases of this type of tumor have been described with a size ranging from 7.5cm up to 10cm (1-6,8-15) and it has been stated that the tumor enlarges during the prenatal period, but growth is arrested after birth (4,9,13).

The tumor that was clinically observed exhibited the typical characteristics of this type of lesion as indicated initially. However it is important to emphasize that the lesion was pedunculated but with a broad base (i.e., it was specifically located in the area of the temporal right upper central and lateral incisors teeth). Although the highest frequency of appearance of this type of lesion is in the alveolar mucosa, mainly in the maxillary alveo-

lar ridge, and specifically the anterior part (i.e., the region of the incisors and temporal canines (1-15)), as in this case. It is also observed in mandible (2-5,7,9,12-14), but less frequently in a maxilla/mandible ratio of 3:1 (1,2,5,8,10-14). Generally, this type of tumor is a single lesion. However multiple tumors have been reported in a range of 5 -16% of the cases (1-5,8-13,15). The congenital epulis in this case occurs in a female patient, which coincides with what is reported in the literature regarding the higher prevalence in females with respect to the males (1-7,9,10,12-15), with the ratio being 8-10:1 (1-5,7,8,10-14). Likewise, there is a greater predisposition for its appearance in people of Caucasian ethnic origin (7,10,12,13), as well as those without a known family pattern or inheritance (13).

The diagnosis of congenital granular cell tumor can be made prenatally (2-4,7,8,10,12,13, 15) when the lesion is large, either by ultrasound (2-4,7,10-13) or magnetic resonance imaging (2-4,7,12,13). However, after birth, a computerized axial tomography, a magnetic resonance imaging of the head or conventional radiography are very useful since they help define (i) the extent of the lesion, (ii) the degree of calcification of the mass, (iii) the presence of any bone defect, and (iv) the involvement of adjacent structures (7,10,13). Although the diagnosis could be based only on clinical criteria, the histopathological study and histochemical findings are essential to define the exact diagnosis and the appropriate management of the tumor, like in this case (1-5,9,12-15).

The etiology of congenital granular cell tumor is unclear (2-6,8-15). The relationship with a hormonal component is reported in the literature. However, there are other theories (1-5,7-12,15) as myoblastic, odontogenic, neurogenic, fibroblastic, histiocytic, endocrinological, which support the mesenchymal origin or reactive origin (2-4,6-10,12-14).

The histopathological study of the congenital granular cell tumor shows the characteristics mentioned above for this case. It is formed by layers of large cells with granular cytoplasm and a non-collagenous vascular stroma (2,4,6-10, 13,14). This type of lesion is negative for protein S-100, contrary to the adult form of granular cell tumors (3,4,9,12-14).

The differential diagnosis of these tumors must be made with different pathologies:

- congenital malformations, such as encephalocele (5,10), dermoid cyst (5,10,15) or teratoma (5,9,10,12).
- benign and malignant neoplasms: hemangiomas (5,9,10,12), lymphatic malformations (5,10), melanotic or pigmented neuroectodermal tumor of childhood (4,5,10,12), rhabdomyosarcoma (5, 10,11), adult granular cell tumor (4), rhabdomyoma (4,9,15), congenital fibrosarcoma (15), osteogenic and chondrogenic sarcoma (11), malignant granular cell myoblastoma (9,11,14), infantile myofibroma, peripheral odontogenic fibroma and neurofibroma (4), lipoma, congenital choristoma (15), schwannoma, hibernoma, fibroma (9), among others.

Treatment for this congenital tumor is surgical excision, which can be performed under local anesthesia or general anesthesia. The choice depends on the size, number of lesions and the location of the tumor (1-5,7-15) In the present case, the surgery was performed under local anesthesia due to the size of the tumor. It was feasible to perform it in this modality, avoiding a complex approach to the female. Another type of treatment is observation, since there are studies that indicate that in some cases there is spontaneous regression (1-3,5-10,12-15). Kokubun *et al.* (2018) state in their study that the reduction in tumor size may result from the release from maternal influence of excessive fetal estrogen produced at birth (6).

It is worth mentioning that when the lesion is excised, it should not be radical or wide, as there is a possibility of damaging the future development of the dentition and creating defects in the soft tissues (13).

No recurrence has been described after surgical removal of the congenital granular cell tumor, despite the fact that there may be incomplete resection and compromised margins (1-10, 12-15). Likewise, no malignant changes have been observed, nor association with congenital syndromes or defects (1,3-5,7-9,11,12,15), although there is literature that associates it with some congenital anomalies (11-13). Also, there are no reports of alteration of the teeth or gingival defects (1,3-5,7, 8,12,15), but Vinay *et al.* (2017), in their work, indicate that the excision of this type of tumor can lead to a notch in the socket (5).

In the case at hand, according to the histopathological report, the resection margins were compromised, but there has been no recurrence of the tumor to this date. In addition, it is important to point out that there is a slight alteration in the eruption sequence since the temporal right upper lateral incisor erupted prior to the temporal right upper central incisor, despite it is soon for it to erupt. It is suspected that this finding may be due to fibrous scar tissue on the alveolar ridge, which caused a slight delay in the eruption of this tooth. Regular follow-up is recommended (13), contrary to what was stated by Vinay *et al.* (2017) and Prabhu *et al.* (2015), who point out that unerupted teeth in the involved area are not involved (5, 13).

CONCLUSION

A congenital granular cell tumor is a benign and rare pathology in newborns, which forces the professional to know its characteristics and its differential diagnosis to determine the appropriate course of action together with the histological study and histochemical findings. The presentation

of this case report as well as the literature review is relevant, as the exact diagnosis is important for proper management of the injury and its prognosis. Although in the present case there were feeding problems due to the tumor, it can also cause respiratory problems, as such, this must be considered given the consequences that it can cause.

CONFLICT OF INTEREST

The authors declare that there is no conflict of interest regarding the publication of this case report.

FUNDING

None.

CONSENT FOR PUBLICATION

Written informed consent for publication was taken from the patient's parents.

AUTHOR CONTRIBUTION STATEMENT

The authors of this work participated in the preparation of the manuscript in its totality according to their profession.

REFERENCES

- Jain N., Singh L. Large congenital epulis in a newborn: diagnosis and management. *Ear Nose Throat J.* 2020; 99 (7): NP79-81. <https://doi.org/10.1177/0145561319851498>
- Kumar R.M., Bavle R.M., Umashankar D.N., Sharma R. Congenital epulis of the newborn. *J Oral Maxillofac Pathol.* 2015; 19 (3): 442-5. <https://doi.org/10.4103/0973-029x.174642>
- Bosanquet D., Roblin G. Congenital epulis: a case report and estimation of incidence. *Int J Otolaryngol.* 2009; 2009: 508780. <https://doi.org/10.1155/2009/508780>
- Cheung J.M., Putras J. Congenital granular cell epulis: classic presentation and its differential diagnosis. *Head Neck Pathol.* 2020; 14 (1): 208-11. <https://doi.org/10.1007/s12105-019-01025-1>
- Vinay K.N., Anjulo L.A., Nitin P., Neha K.V., Dhara D. Neumann's tumor: a case report. *Ethiop J Health Sci.* 2017, 27 (2): 189-92. <https://doi.org/10.4314/ejhs.v27i2.11>
- Kokubun K., Matsuzaka K., Akashi Y., Sumi M., Nakajima K., Murakami S., Narita M., Shibahara T., Inoue T. Congenital epulis: a case and review of the literature. *Bull Tokyo Dent Coll.* 2018; 59 (2): 127-32. <https://doi.org/10.2209/tdcpublication.2017-0028>
- Gupta D., Panda S.S., Yadav D.K., Kumar B., Bagga D., Achary S.K. Congenital epulis: a rare lesion. *Journal of Clinical Neonatology.* 2014; 3 (4): 220-2. <http://dx.doi.org/10.4103/2249-4847.144755>
- Bang K.O., Bodhade A.S., Diver A.M. Congenital granular cell epulis of a newborn. *Dent Res J.* 2012; 9 (7): S136-8. <http://dx.doi.org/10.4103/1735-3327.107957>
- Rezende K.M., Pires Côrrea F.N., Pires Côrrea J.P., Pires Côrrea M.S., Bönecker M. Histogenesis and clinical analysis of 2 cases of congenital gingival granular cell tumor. *J Clin Diagn Res.* 2015; 9 (1): ZD03-5. <https://dx.doi.org/10.7860%2FJCDR%2F2015%2F10048.5409>
- Dhareula A., Jaiswal M., Goyal A., Gauba K. Congenital granular cell tumor of the newborn - Spontaneous regression or early surgical intervention. *J Indian Soc Pedod Prev Dent.* 2018; 16 (3): 319-23. https://doi.org/10.4103/JISPPD.JISPPD_1187_17
- Canavan-Holliday K.S., Laeson R.A. Anaesthetic management of the newborn with multiple congenital epulides. *BJA.* 2004; 93 (5): 742-4. <https://doi.org/10.1093/bja/aeh255>

12. Vijayalakshmi K.R., Priyanka R., Pai A.S. A rare case report of congenital granular cell epulis. *J Indian Acad Oral Med Radiol.* 2021; 33 (1): 99-102. https://doi.org/10.4103/jiaomr.jiaomr_148_20
13. Prabhu N., McDonald J., Cass D., Coleman H., Cameron A.C. Congenital granular cell tumour: an unusual antenatal presentation with a 12-year follow-up. *SADJ.* 2015; 70 (2): 50-2. <https://hdl.handle.net/10520/EJC168127>
14. Kato H., Nomura J., Marsumura Y., Yanase S., Nakanishi K., Tagawa T. A case of congenital granular cell epulis in the maxillary anterior ridge: a study of cell proliferation using immunohistological staining. *J Maxillofac Oral Surg.* 2013; 12 (3): 333-7. <https://doi.org/10.1007/s12663-011-0248-3>
15. Gnassingbe K., Mhluendo-Agbolan K.A., Bissa H., Amegbor K., Blanchard Noumeden N., Egbohohou P., Mama W., Akakpo-Numado G.K., Tekou H. Congenital giant epulis obstructing oral cavity: newborn emergency. *Pan African Medical Journal.* 2014; 17 (195): 1-4. <https://dx.doi.org/10.11604%2Fpamj.2014.17.195.3023>



Attribution (BY-NC) - (BY) You must give appropriate credit, provide a link to the license, and indicate if changes were made. You may do so in any reasonable manner, but not in any way that suggest the licensor endorses you or your use. (NC) You may not use the material for commercial purposes.